CASE SPOTLIGHT | Medial Osteoarthritis Treated With Genicular Artery Embolization

By Keerthi Prasad, MD

PATIENT PRESENTATION

A woman in her early 60s presented with chronic, worsening bilateral knee pain, with the left knee being more affected than the right. The pain had been worsening for approximately 8 months and was exacerbated by standing and ambulation, significantly affecting her ability to work at a restaurant. She had previously undergone physical therapy, multiple long-acting corticosteroid injections, and a three-injection viscosupplementation series, but these treatments were no longer providing sufficient relief. A prior x-ray had demonstrated Kellgren-Lawrence grade 3 osteoarthritis (OA) of the left knee. The patient was averse to surgical intervention due to associated lengthy recovery.

Initial pain assessment revealed a visual analog scale (VAS) score of 8/10 and an Oxford Knee Score of 19, indicating severe symptoms and poor function. Physical examination of the left knee revealed no scars, normal muscle tone, and no joint laxity, but there was mild fullness in the popliteal fossa and tenderness to palpation along the superior and inferior aspects of the medial joint. The overall diagnosis was worsening medial compartment OA of the left knee.

PROCEDURAL OVERVIEW

The procedure was performed via a left dorsalis pedis artery approach, where a 4-F, 10-cm pedal sheath was placed under ultrasound guidance using standard technique. A 4-F angled hydrophilic catheter and 0.035-inch-diameter hydrophilic guidewire were used to navigate to the level of the popliteal artery. An angiogram at this level demonstrated a prominent superior medial genicular artery (SMGA) (Figure 1A).

A 2.5-F, 110-cm Cantata® microcatheter (Cook Medical) and an 0.018-inch-diameter wire guide were then used to selectively cannulate the SMGA. A subsequent angiogram showed a hypervascular "blush" in the medial femoral condyle (Figure 1B), and this injection successfully reproduced the patient's typical knee pain, confirming the pathological target.

Embolization was performed with a dilute suspension of 100-µm beads, which were delivered in aliquots of up to 0.2 mL for a total volume of 0.5 mL, to occlude the abnormal neovascularity (Figure 1C). Upon completion, the devices were removed uneventfully, and hemostasis was achieved using ultrasound-assisted compression.

OUTCOME AND FOLLOW-UP

The patient experienced a mild increase in pain on postprocedure day 3. However, by day 20, her pain had significantly improved, with her VAS score dropping to 3/10 and her Oxford Knee Score increasing to 33. This clinical improvement was maintained at her 3-month follow-up, with a VAS score of 3/10 and an Oxford Knee Score of 31.

PHYSICIAN DISCUSSION

This case demonstrates the efficacy of genicular artery embolization (GAE) as a safe and effective nonsurgical option for treating symptomatic knee OA. The procedure successfully targeted the specific hypervascularized area, which was confirmed by reproduction of the patient's pain on injection, leading to significant and sustained pain relief. The use of 100-µm beads effectively reduced arterial inflow, resulting in a marked improvement in the patient's symptoms and quality of life. The Cantata microcatheter was very convenient and useful in this case. The ability to maintain position easily and its shorter available length allowed for comfortable ergonomics. Furthermore, there is no risk of clogging during embolization. GAE is a valuable treatment option for patients who are not candidates for or do not desire surgery. ■

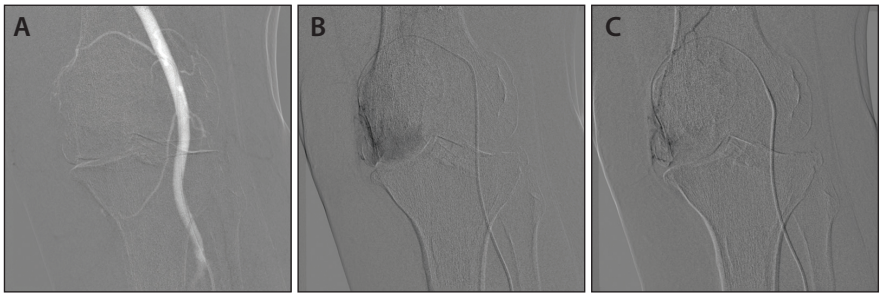

Figure 1. Initial angiogram demonstrating the prominent SMGA (A). Selective angiogram showing hypervascular medial femoral condyle blush and reproduction of the patient's pain (B). Postembolization image after delivery of 100-µm beads (C).